

ECC FOR DISCUSSION

*H Medicine Unit
Chief*

Prof Dr.M.Natarajan MD

Asst Professors


Dr Valli devi MD

Dr Sridharan MD

Dr. shanmuganadhan MD

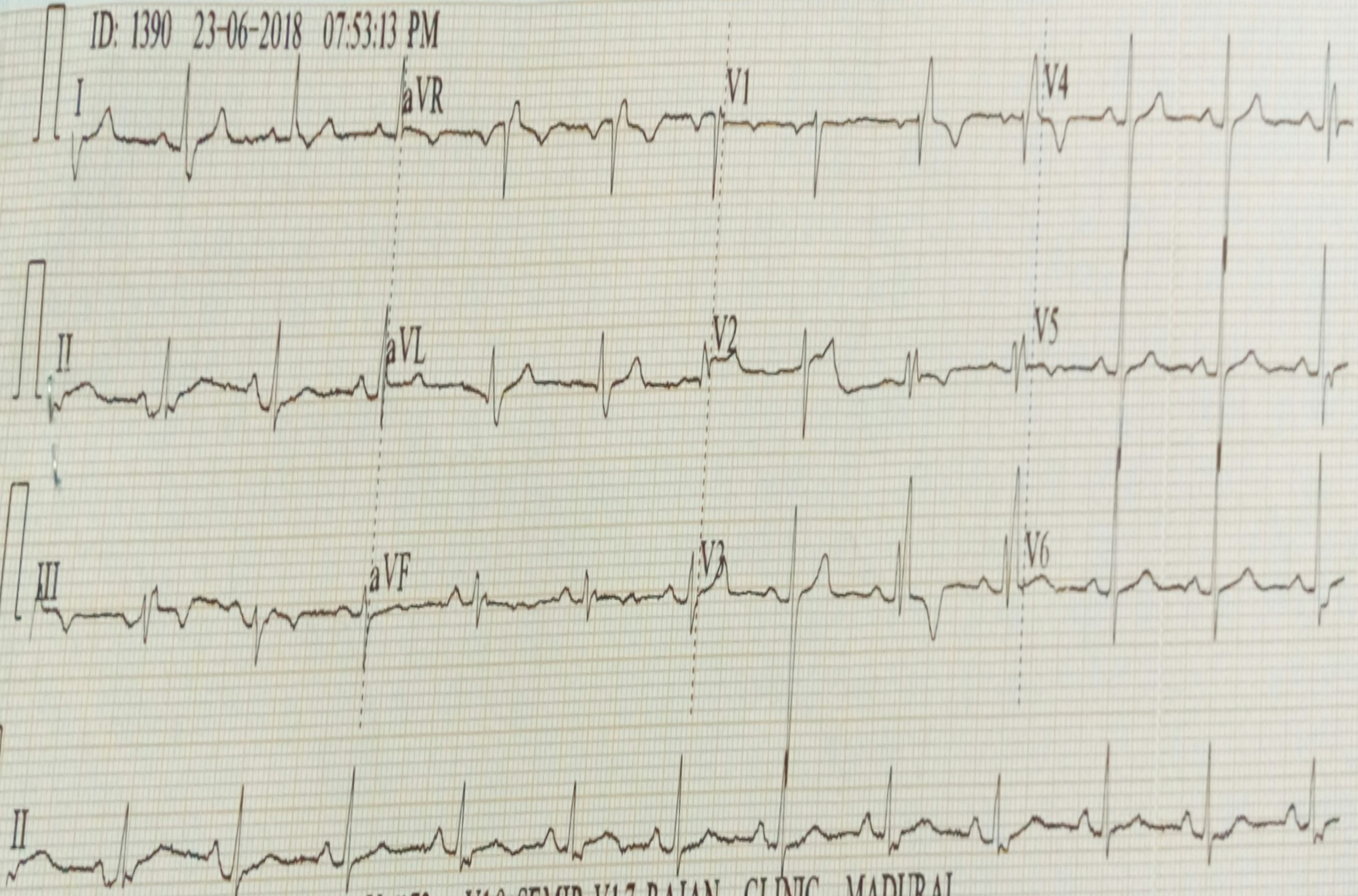
Presentor

Dr. P. muthukrishnan

- 
- *60 years old female known case of DIABETES MELLITUS came for routine check up*
 - *No symptoms*
 - *Vitals : stable*

BPL

ID: 1390 23-06-2018 07:53:13 PM



0.67~45Hz AC50 25mm/s 10mm/mV ♥72 V1.0 SEMIP V1.7 RAJAN CLINIC MADURAI

ECC

- HR: around 68 /mint
- Normal sinus
- Normal axis
- PR: 120 milli sec
- QT: 340 milli sec
- Intermittent S wave slurring in lead I, aVL
- Intermittent rsR patten in V1-V3

Discussion

Complete intermittent

- *Rate limited*

RBBB

Incomplete Intermittent RBBB

- *CAO*
- *Myocarditis*
- *Pulmonary embolism*
- *Post cardiac surgery*
- *RVH*

Other causes

- *APC with aberrant conduction*
- *APC conduction pass through ventricles when right bundle branch is refractory*
- *Intermittent pre excitation (pass through mahaim fibre)*