

# INTERESTING CT & MRI DISCUSSION

3<sup>rd</sup> MEDICAL UNIT

PROF...DR.M.NATARAJAN M.D,

ASST.PROF.;

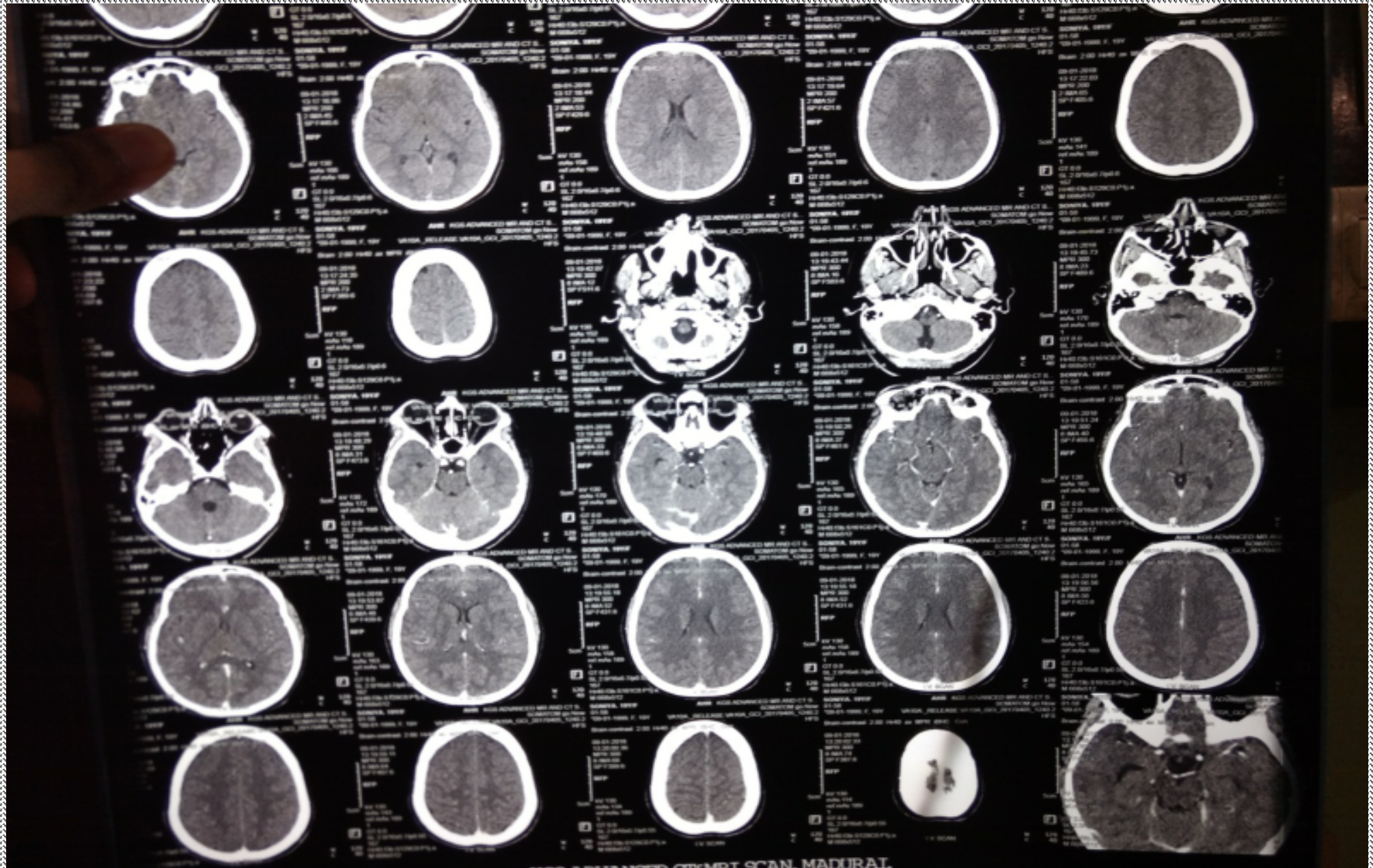
DR.SYED BAHAVUDEEN HUSSANI M.D,

DR.VALLIDEVI M.DM,

DR.SHANMUGANATHAN M.D,

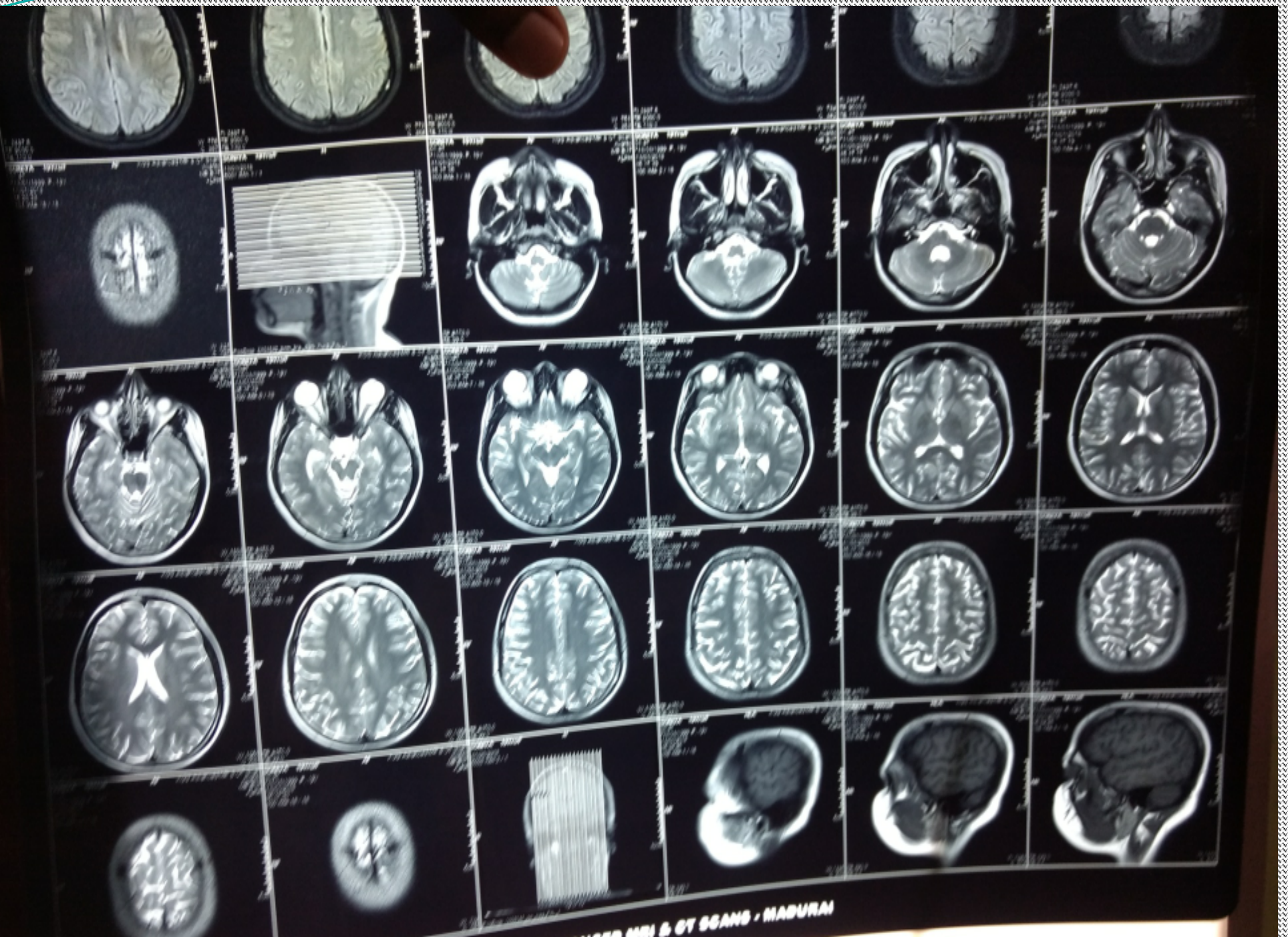
- 19 yr old girl was admitted for C/O new onset GTCS.
- Lasting for 10 mins followed by postictal LOC and later confusion for 3 hours..
- H/O decreased scholastic performance.
- H/O memory disturbance present.

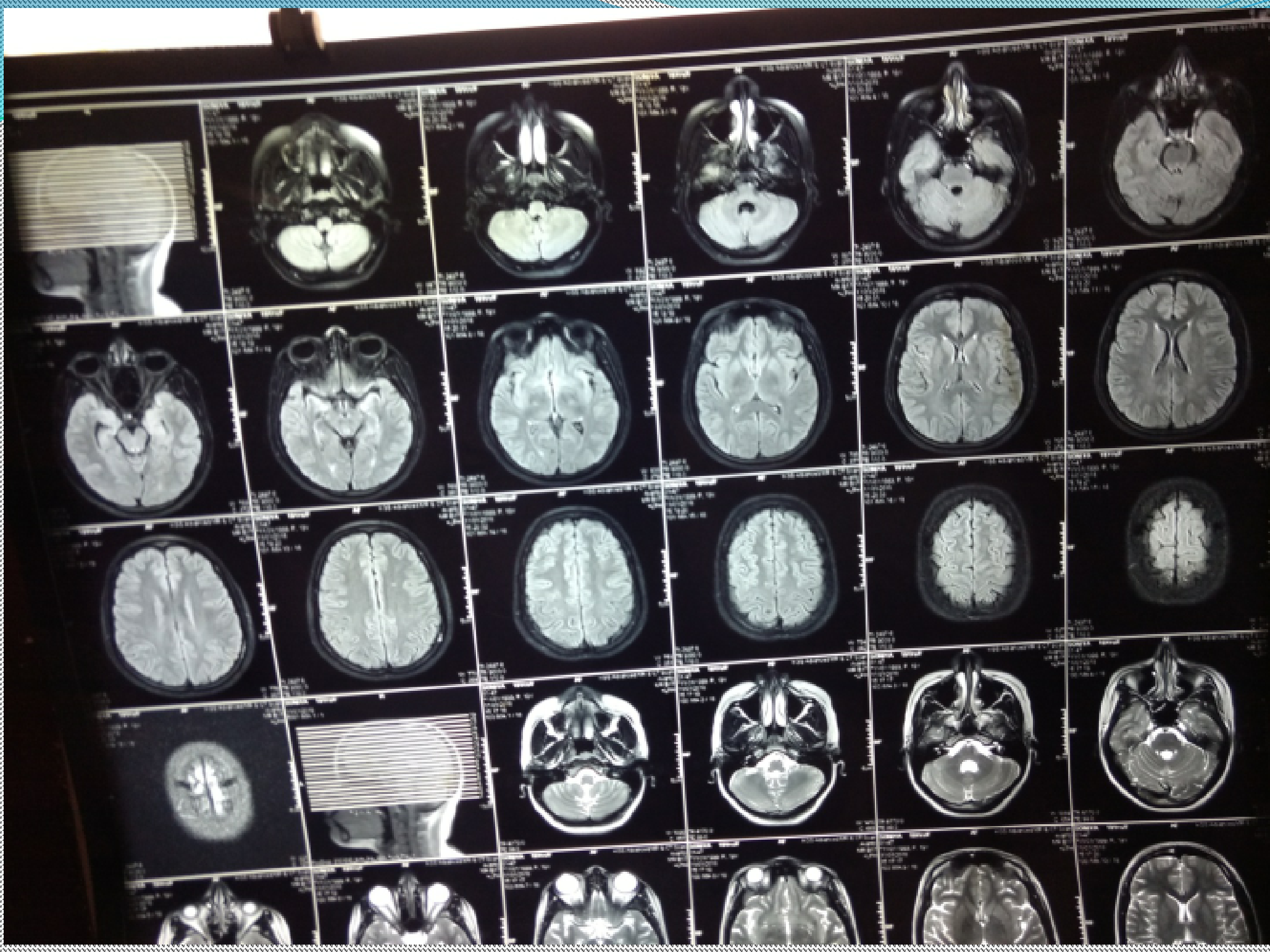
# CT BRAIN



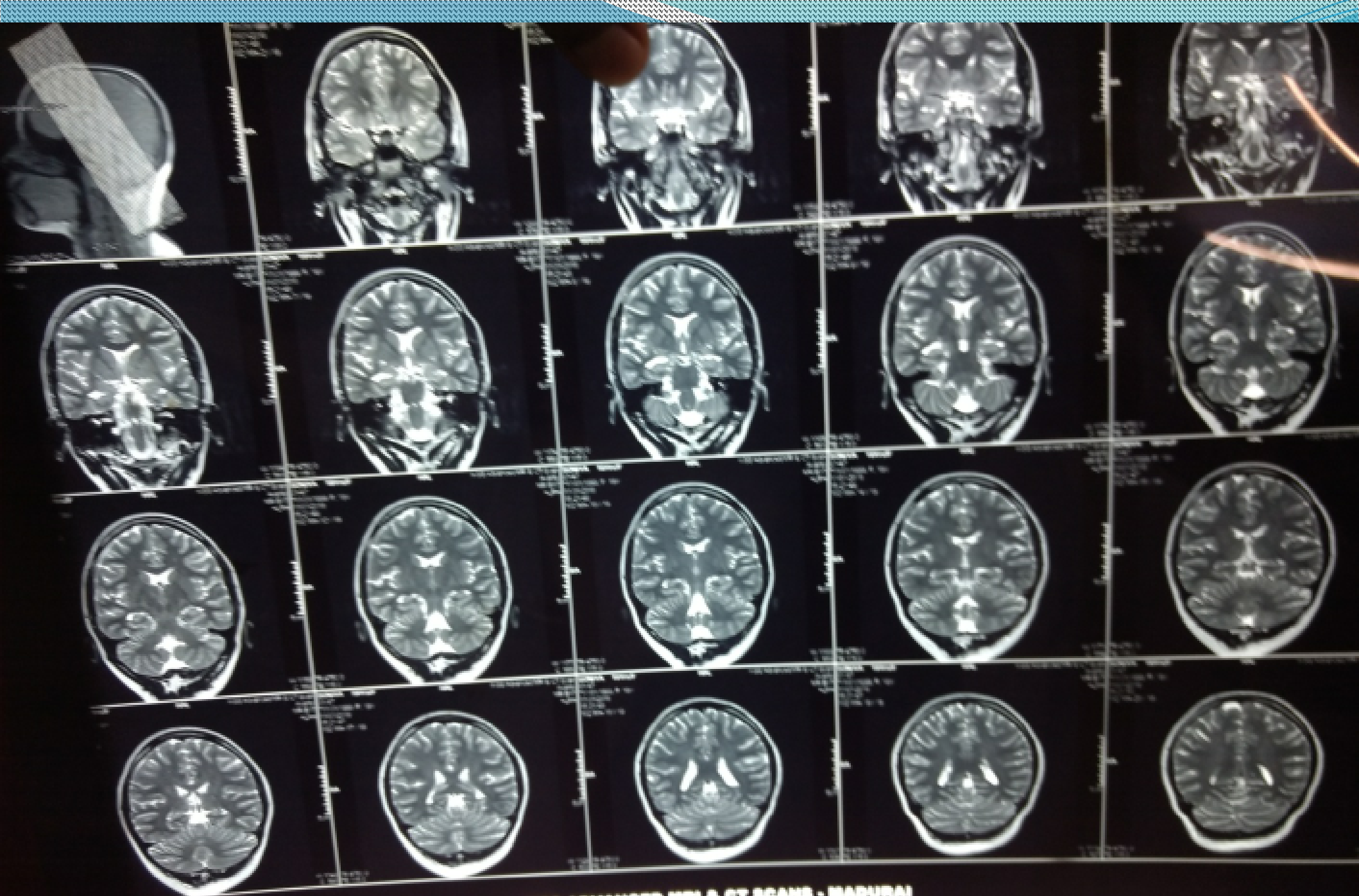


# MRI BRAIN







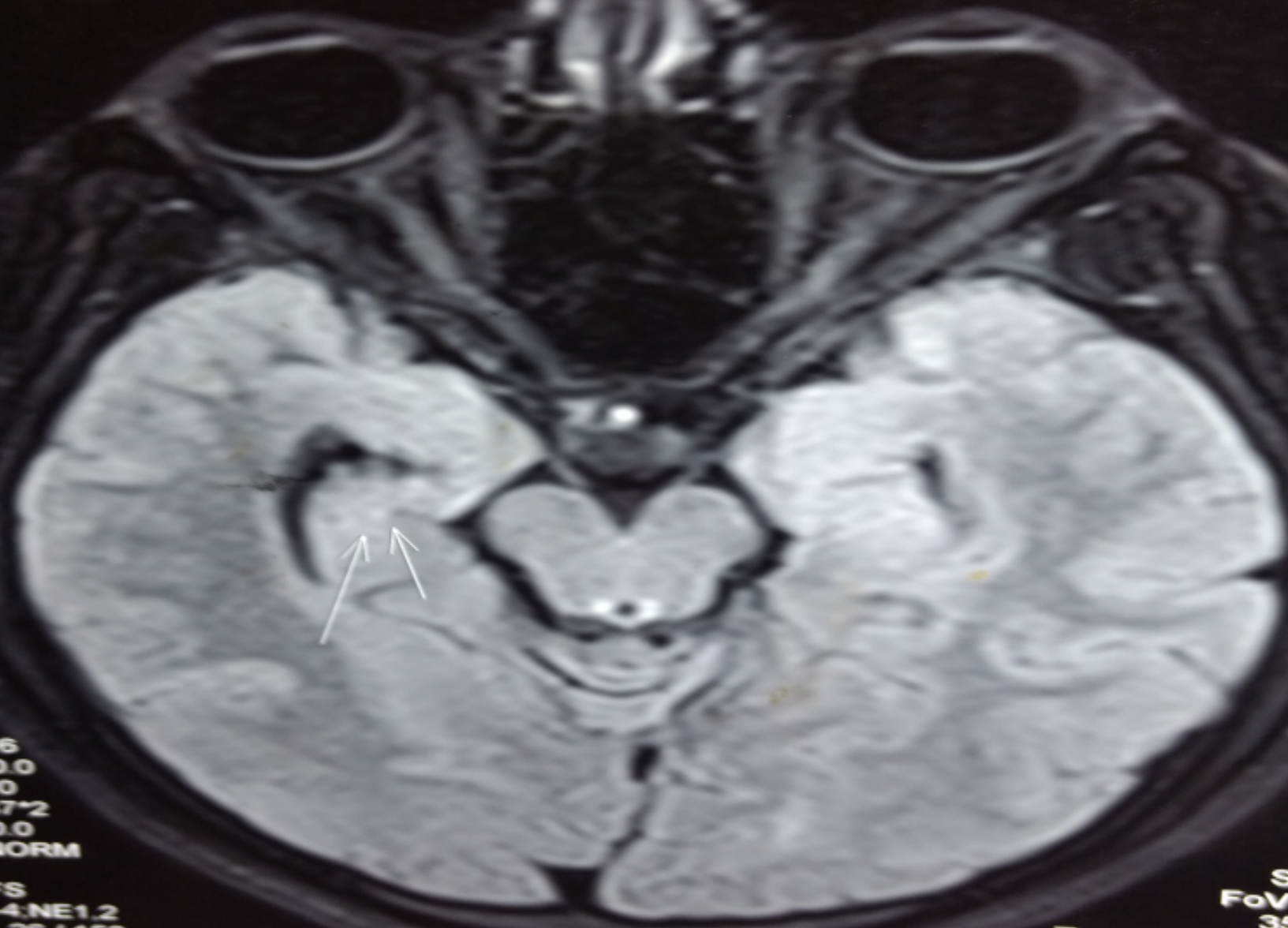


KGS ADVANCED MRI & CT SCANS - MADURAI

id1\_15 / 150  
IIYA 19Yrs/F  
7  
01/1999  
3Y  
01/1999, F, 19Y  
DY 1  
1/2018  
0:31  
A6/1

A

KGS Advance



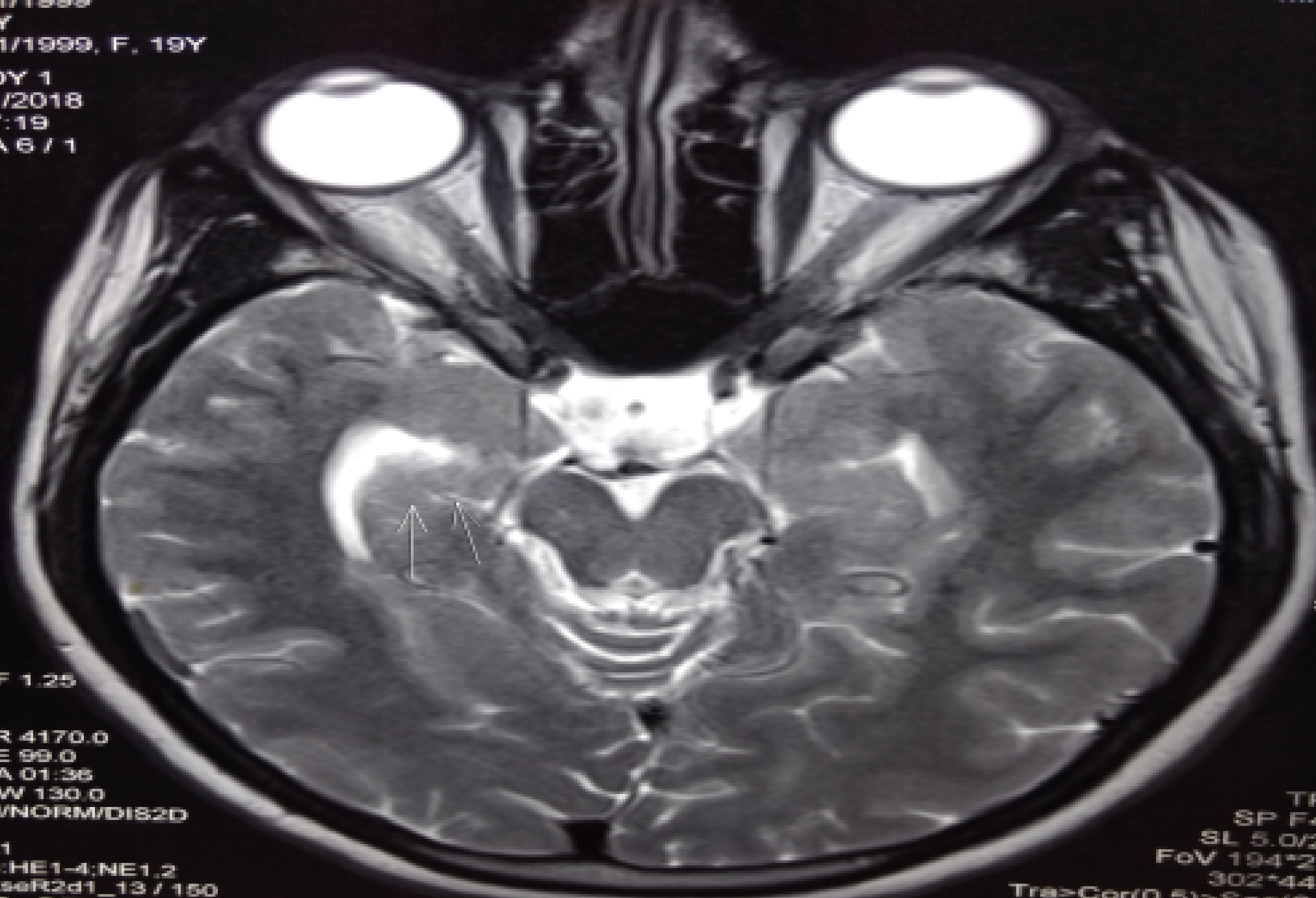
F 1.27  
I 2497.6  
R 9000.0  
E 110.0  
A 54.47\*2  
W 190.0  
VND/NORM  
1/IR/FS  
2:HE1-4:NE1.2  
tr2d1\_26 / 150

E  
TP 0  
SP F4.8  
SL 5.0/2.0  
FoV 201\*230  
358\*512s I  
Tra>Cor(0.5)>Sag(0.0)  
W 785  
C 369

KGS ADVANCED MRI ANI

19Y  
/01/1999, F, 19Y

IDY 1  
1/2018  
7:19  
JA 6 / 1



MF 1.25

TR 4170.0  
TE 99.0  
TA 01:36  
BW 130.0  
M/NORM/DIS2D

A1  
C:HE1-4:NE1,2  
9 \*1seR2d1\_13 / 150

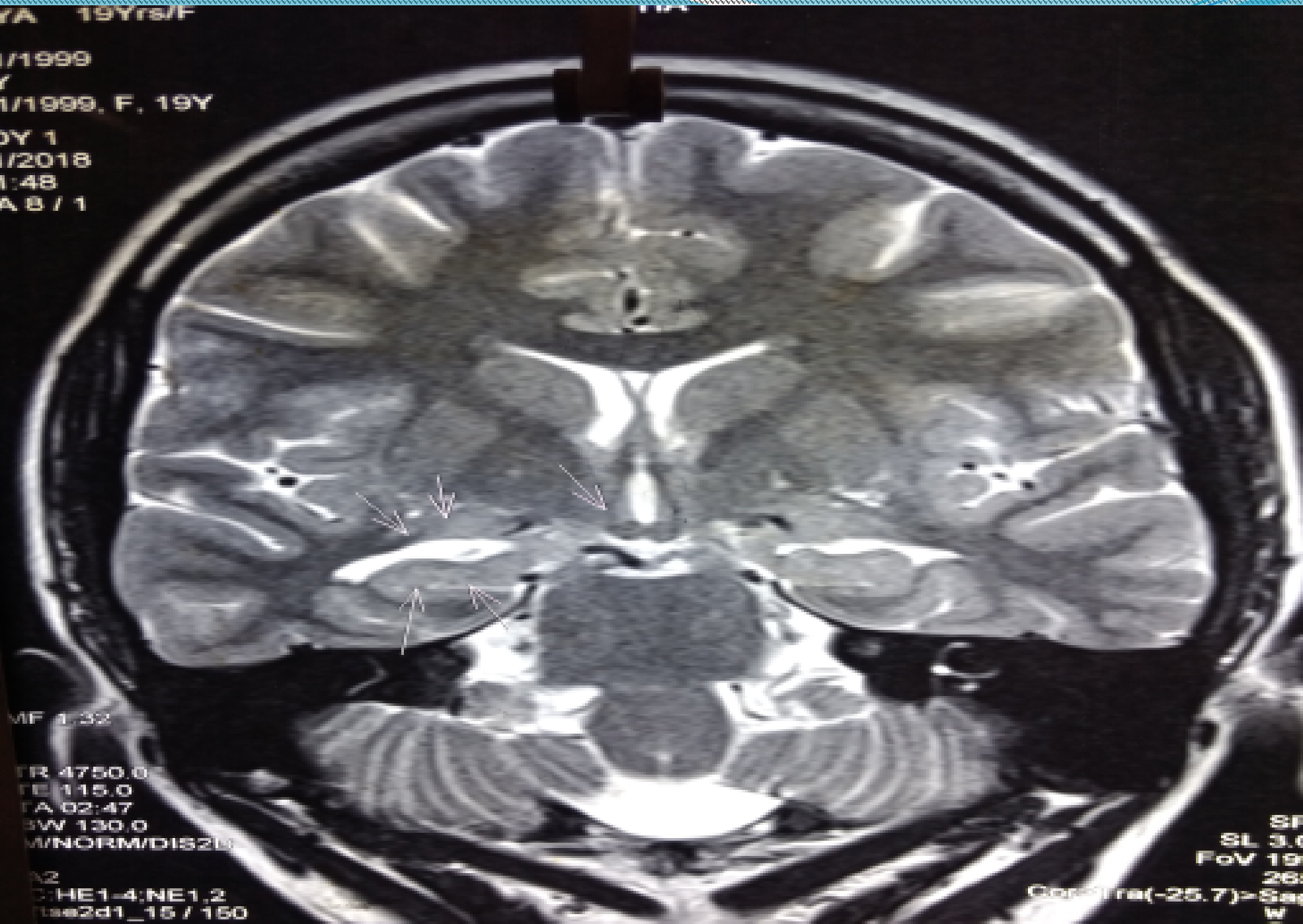
ND CT SCANS - MADURAI

TP  
SP F4.1  
SL 5.0/2.0  
FoV 194\*230  
302\*448  
Tra>Cor(0.5)>Sag(0.0  
W 1408  
C 655



BONIYA 19Yrs/F  
01-47  
11/01/1999  
19Y  
11/01/1999, F, 19Y

STUDY 1  
11/01/2018  
15:21:48  
IMA 8 / 1



MF 1:32

TR 4750.0  
TE 115.0  
TA 02:47  
BW 130.0  
M/NORM/DIS2D

A2  
C:HE1-4;NE1,2  
fse2d1\_15 / 150  
BONIYA 19Yrs/F  
01-47  
11/01/1999  
19Y  
11/01/1999, F, 19Y

A

SP R  
SL 3.000  
FoV 1990  
265°  
Cor(0)ra(-25.7)>Sag(0)

KGS Advanced MR & CT Sc  
Ave  
MR B  
H

SONIYA 19YrsF  
01-47  
11/01/1999  
F, 19Y  
11/01/1999, F, 19Y  
STUDY 1  
11/01/2018  
15:21:48  
3 MA 8 / 1

HA

KGS Advanced MR & CT Scan SONIYA 19YrsF  
Avento 01-47  
MR 817 11/01/1999  
HFS F, 19Y  
+LPH 11/01/1999, F, 19Y

STUDY 1  
11/01/2018  
15:21:48  
3 MA 16 / 1

HA

KGS Advanced MR & CT Scan  
Avento  
MR 817  
HFS  
+LPH

R

MF 132

TR 4750.0  
TE 118.0  
TA 03:47  
BW 130.0  
MNORM/D0820

A2  
C:HE1-4:NE1.2  
Tse2d1\_15 / 150  
SONIYA 19YrsF  
01-47  
11/01/1999  
F, 19Y  
11/01/1999, F, 19Y

STUDY 1  
11/01/2018  
15:20:31  
4 MA 8 / 1

A

KGS Advanced MR & CT Scan SONIYA 19YrsF  
Avento 01-47  
MR 817 11/01/1999  
HFS F, 19Y  
+LPH 11/01/1999, F, 19Y

STUDY 1  
11/01/2018  
15:17:18  
3 MA 6 / 1

5cm

MF 132

TR 4750.0  
TE 118.0  
TA 03:47  
BW 130.0  
MNORM/D0820

C:HE1-4:NE1.2  
Tse2d1\_15 / 150  
SONIYA 19YrsF  
01-47  
11/01/1999  
F, 19Y  
11/01/1999, F, 19Y

A

KGS Advanced MR & CT Scan  
Avento  
MR 817  
HFS  
+LPH

SP F  
SL 3.0  
FoV 190  
280  
C

MR



THANK YOU